

IV JORNADA DE CIRUGÍA DEL PIE BARCELONA – OPORTO
Clínica N. S. del Remei Barcelona

FRACTURA “OS PERONEUM”

P. Marcello, J.C. Serfaty, A. Rosinés, E. Otero, E. Lucas, X. Gomez Bonsfills
Unidad de pie y tobillo



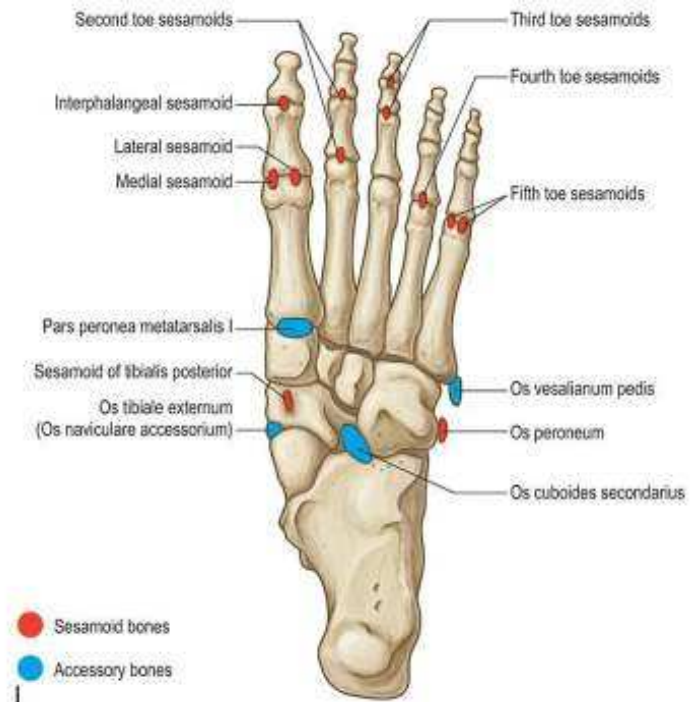
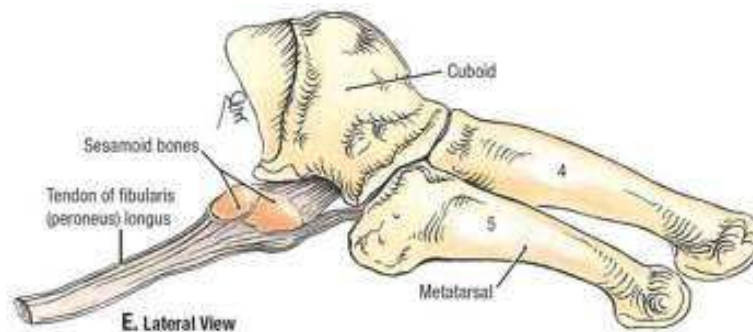
Clínica COPERNICO MC-MUTUAL
Jefe de Servicio X. Gomez Bonsfills



El “os peronuem” es un hueso sesamoideo del pie presente entre el 5 y el 26% de la población.

De forma ovalar, redonda o irregular, a veces bipartido o multipartido.

Localizado “intra-sustancia” en el recorrido del tendón peroneo largo a nivel de su paso por debajo del cuboides.



FRACTURA “OS PERONEUM”

- Frecuencia rara
- Pérdida de funcionalidad del tendón peroneo largo.
- Inestabilidad, dolor y deformidad progresiva del pie.

TRATAMIENTO RECOMENDADO

Conservador: inmovilización

Quirúrgico: reparación de la fractura
exéresis de parte o de todo el osículo con reparación tendinosa
tenodesis del tendón peroneo largo al tendón peroneo corto.

TRATAMIENTO RECOMENDADO

Table 1. Treatment of fractures of os peroneus

Author(s)	Number of patients	Treatment	Followup (months)	Results	Complications
Brav and Chewning [3] (1949)	1	Nonoperative	2	Satisfactory	None
Grisolia [5] (1963)	1	OP excision and PL repair	6	Satisfactory	None
Mains and Sullivan [8] (1973)	1	Proximal OP excision and PL suture to distal OP fragment	18	Satisfactory	None
Tehraneh et al. [19] (1984)	1	Suture repair of os peroneus	22	Satisfactory	None
Peacock et al. [11] (1986)	1	Suture repair of proximal and distal fragments	12	Poor	RSD
Pessina [13] (1988)	1	Nonoperative	16	Satisfactory but eversion weakness	None
Bianchi et al. [1] (1991)	3	Nonoperative	Not reported	Satisfactory in 2 patients. Poor in 1 patient with eversion weakness	None
Peterson and Stinson [14] (1992)	5	OP excision and PL repair	12–28	Excellent in 4 patients Good in 1 patient	None
Sobel et al. [18] (1994)	10 total, 6 with OP disruption	Nonoperative in 2; OP excision and PL repair in 2; OP excision and PL to PB tenodesis in 2	Not reported	Nonop: 1 Excellent, 1 Good; OP excision/PL repair: 2 Good; OP excision/tenodesis: 1 Excellent, 1 Good	2nd metatarsal stress fx in 1 pt treated by tenodesis
Sammarco [15] (1995)	14 total, 3 with OP disruption	OP excision and PL repair in 2; OP excision and fascial graft in 1	2–20	OP excision/PL repair: 1 Poor, 1 unrelated death 2 mos postop; OP excision/fascial graft: Excellent	None
Patterson and Cox [10] (1999)	1	OP excision and PL to PB tenodesis	6	Excellent	None
Okazaki et al. [9] (2003)	1	OP excision and PL repair	16	Satisfactory	None

OP = os peroneum; PL = peroneus longus; PB = peroneus brevis.



Lasso Stitch with Peroneal Retinaculoplasty for Repair of Fractured Os Peroneum. A Report of Two Cases
 Vincent James Sammarco MD, Daniel J. Cuttica DO, G. James Sammarco MD
 Clin Orthop Relat Res (2010) 468:1012–1017



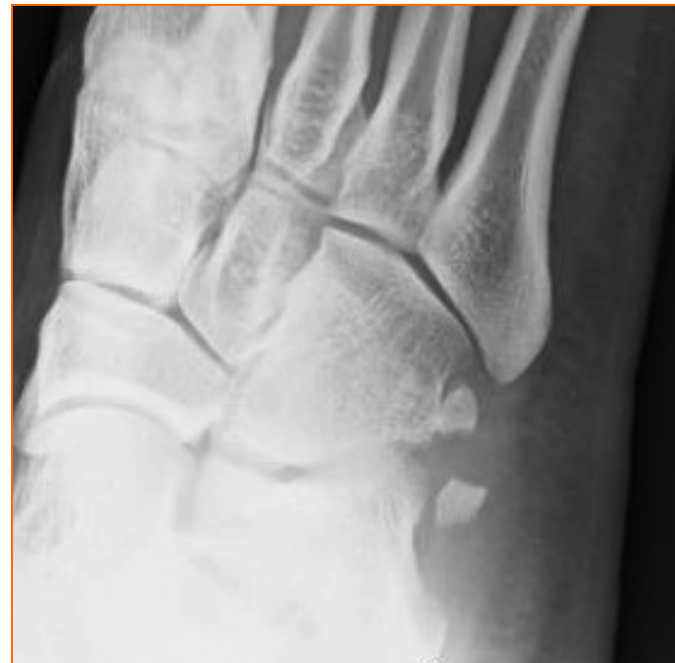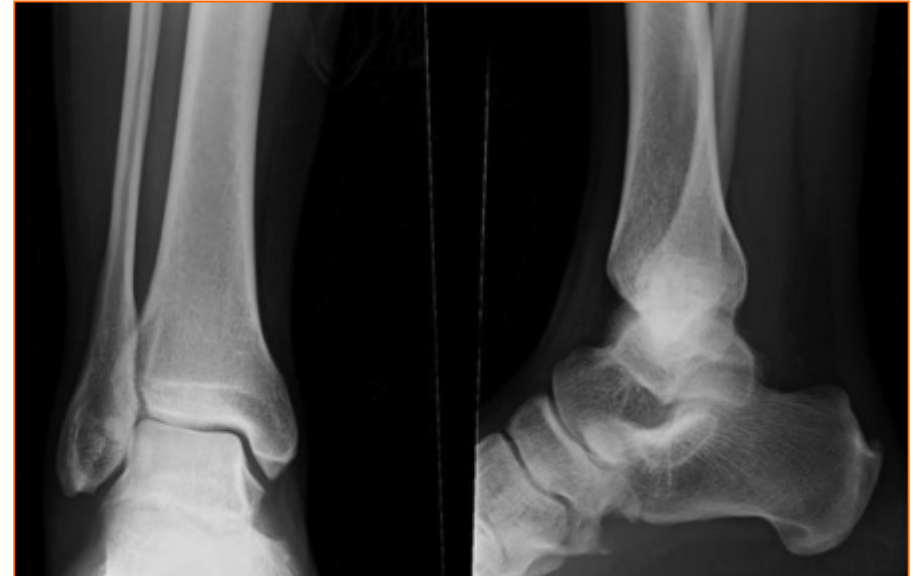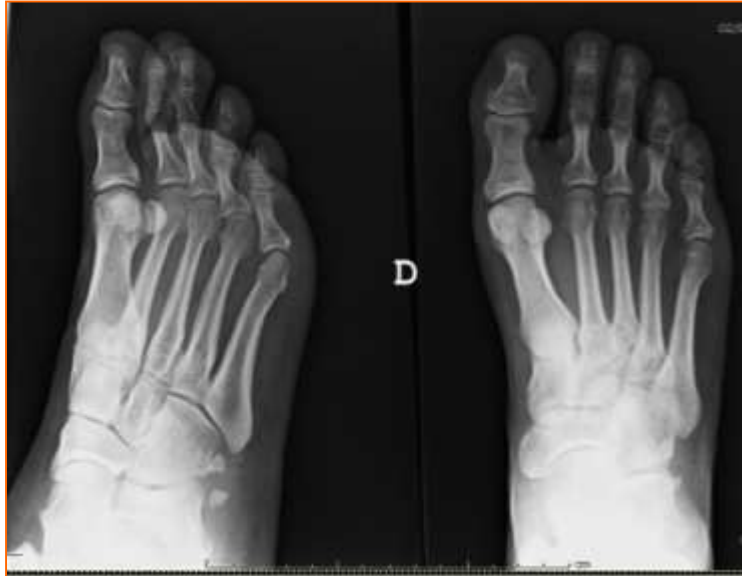CASO CLÍNICO

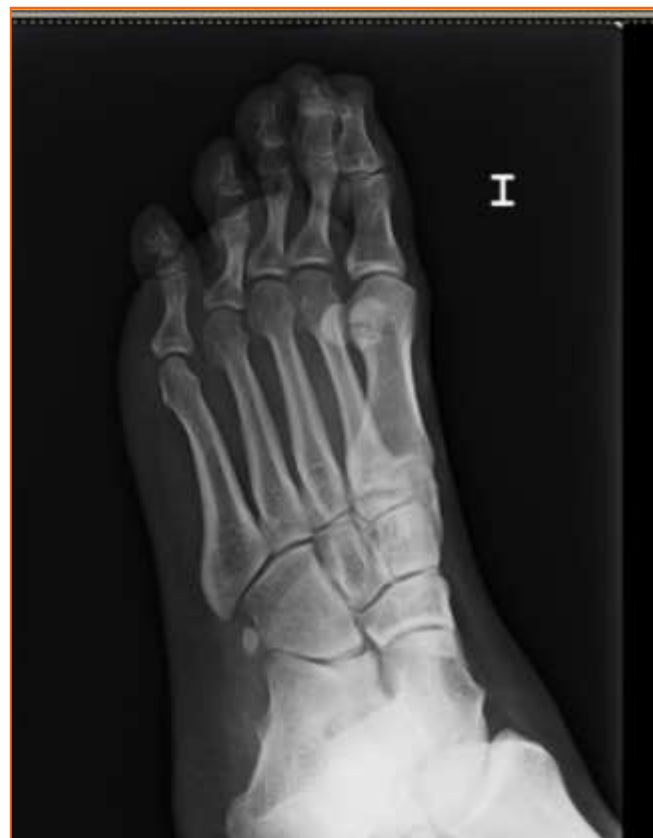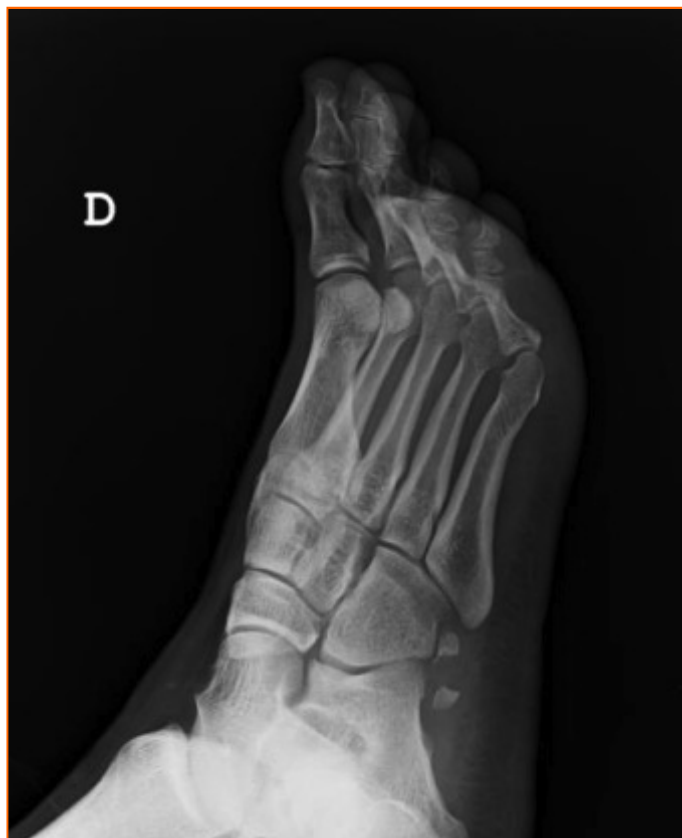Paciente de 45 años de edad, trabajador en una cadena de montaje.

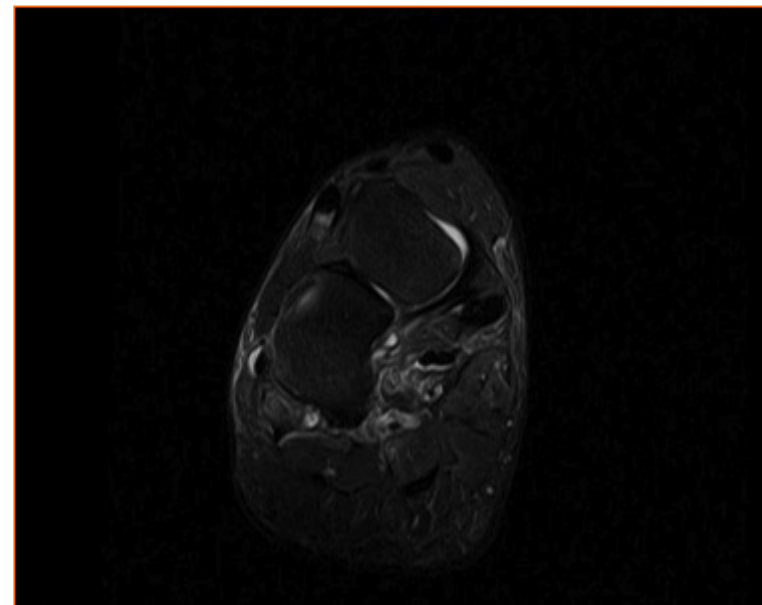
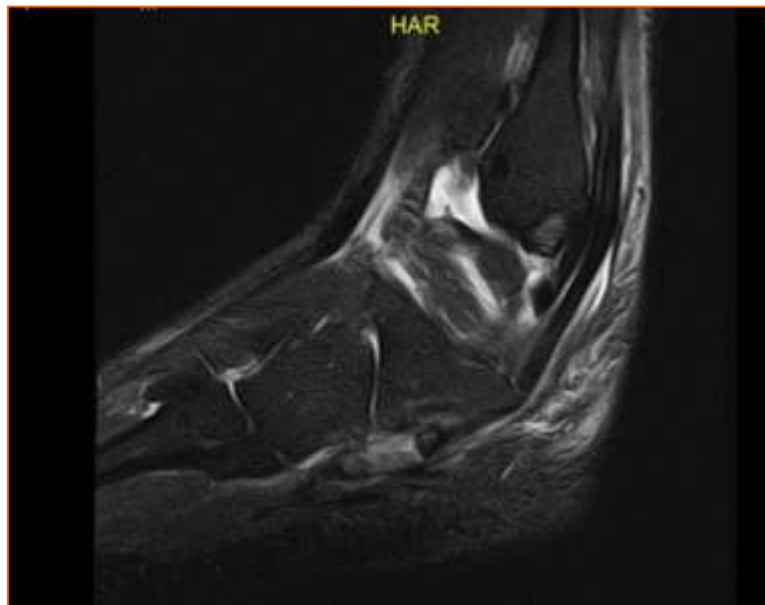
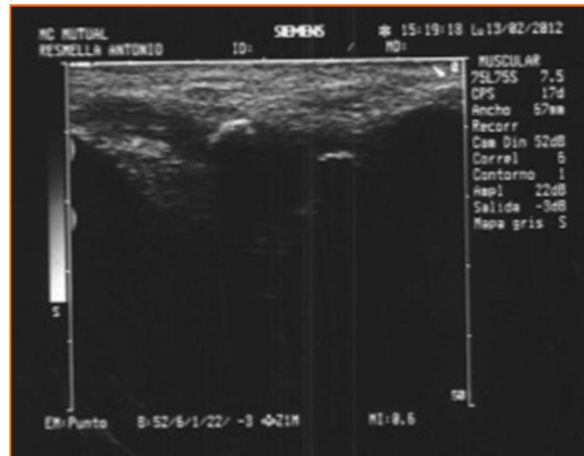
Sufrió entorsis de tobillo con dolor, tumefacción e impotencia funcional en tobillo D.

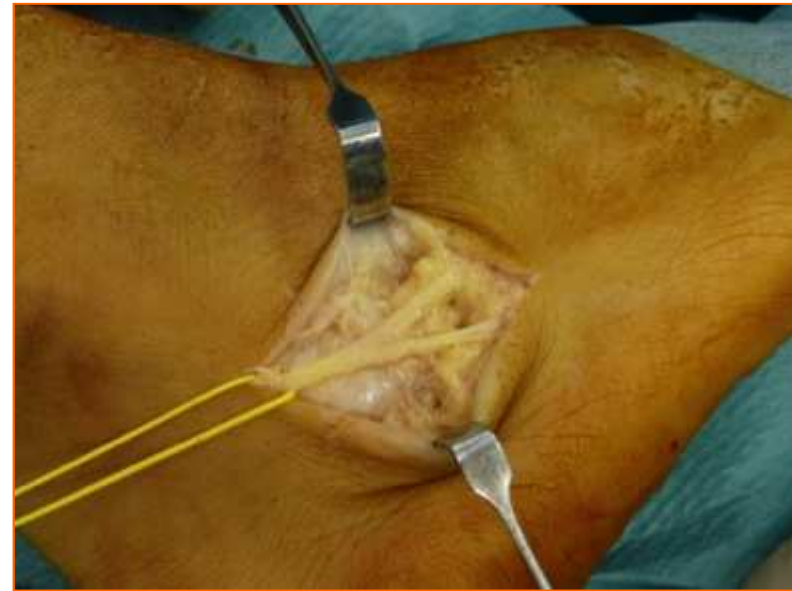
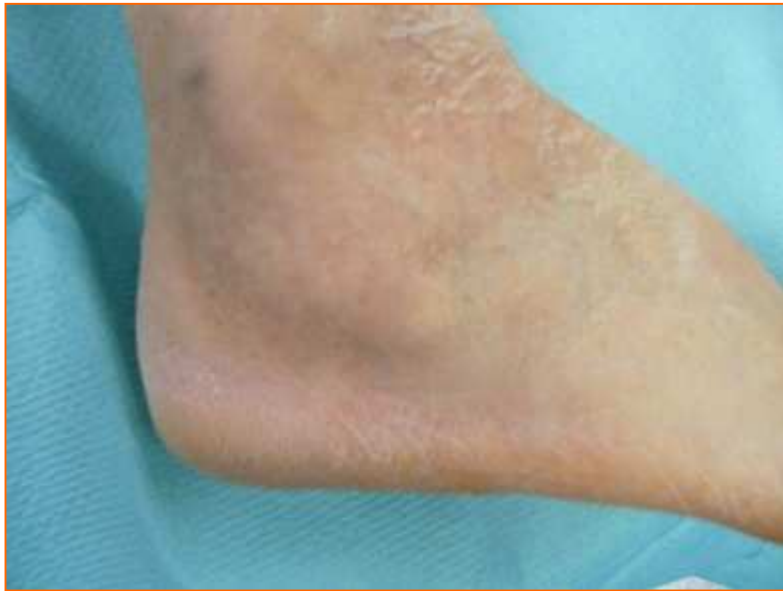El examen radiográfico mostró una fractura de os peroneum con retracción de 1.1 cm de su fragmento proximal.

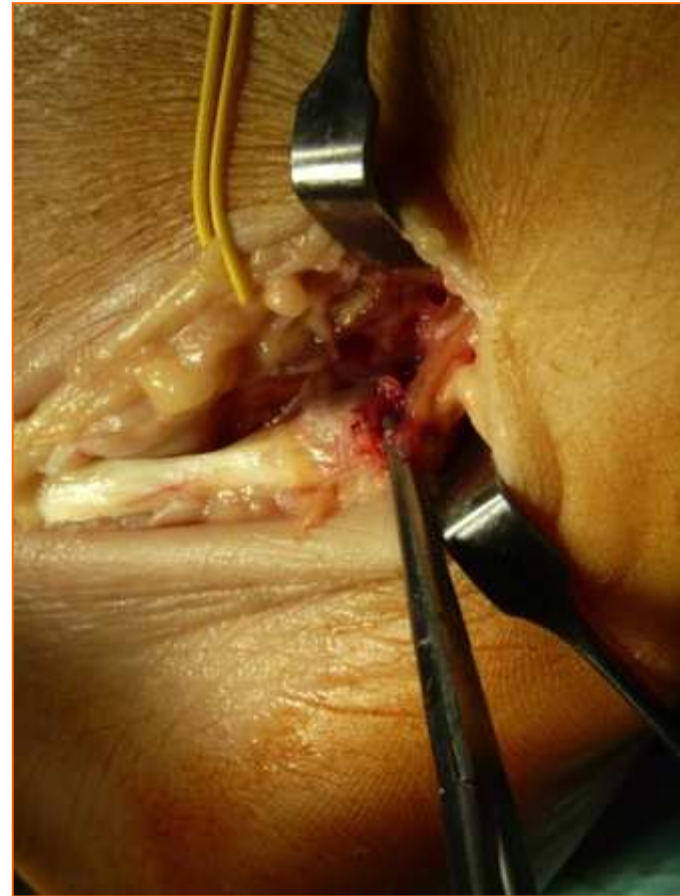
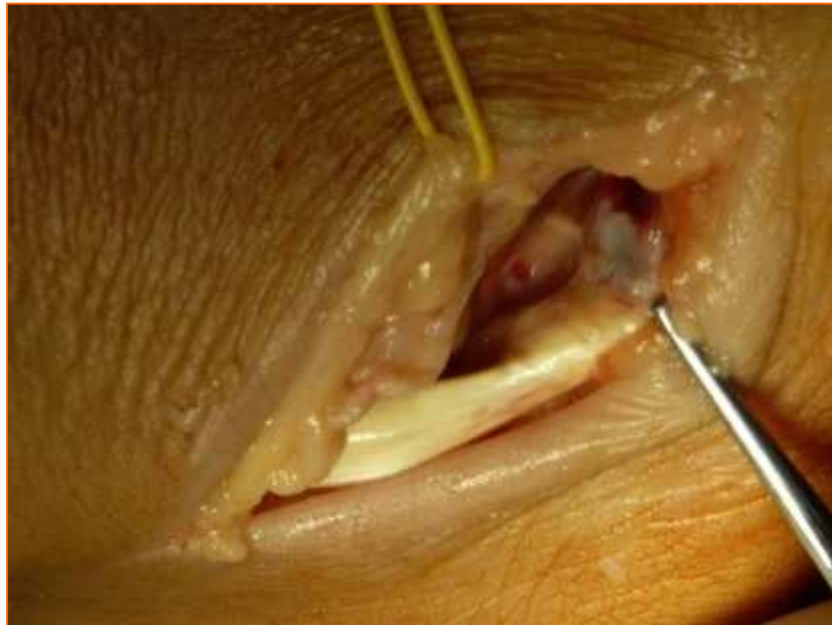Fue inicialmente tratado en servicio de urgencias con inmovilización.

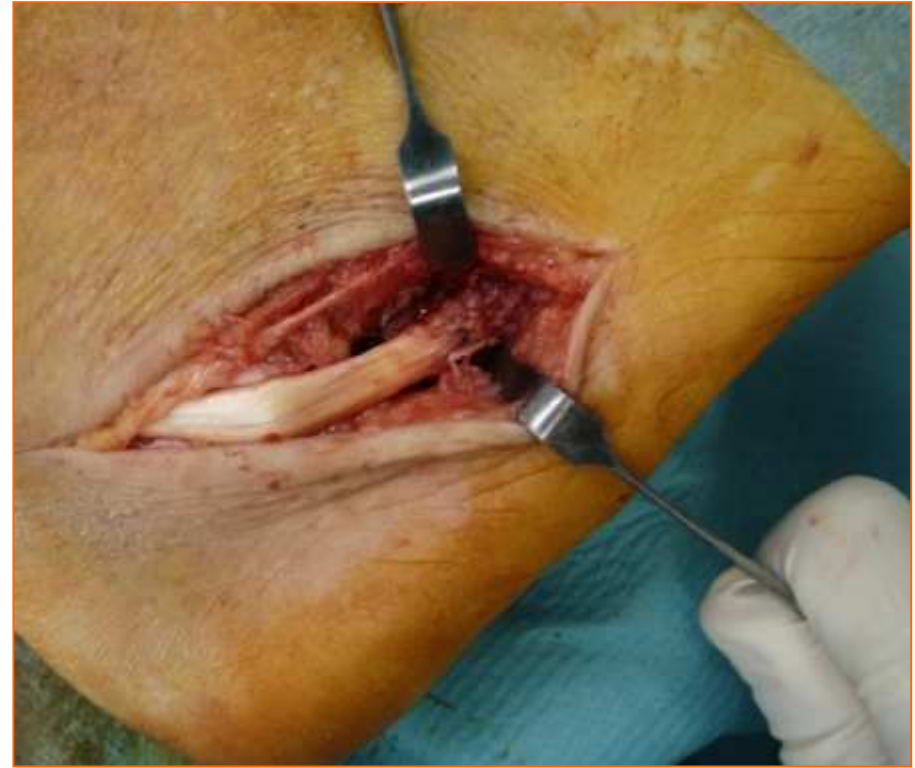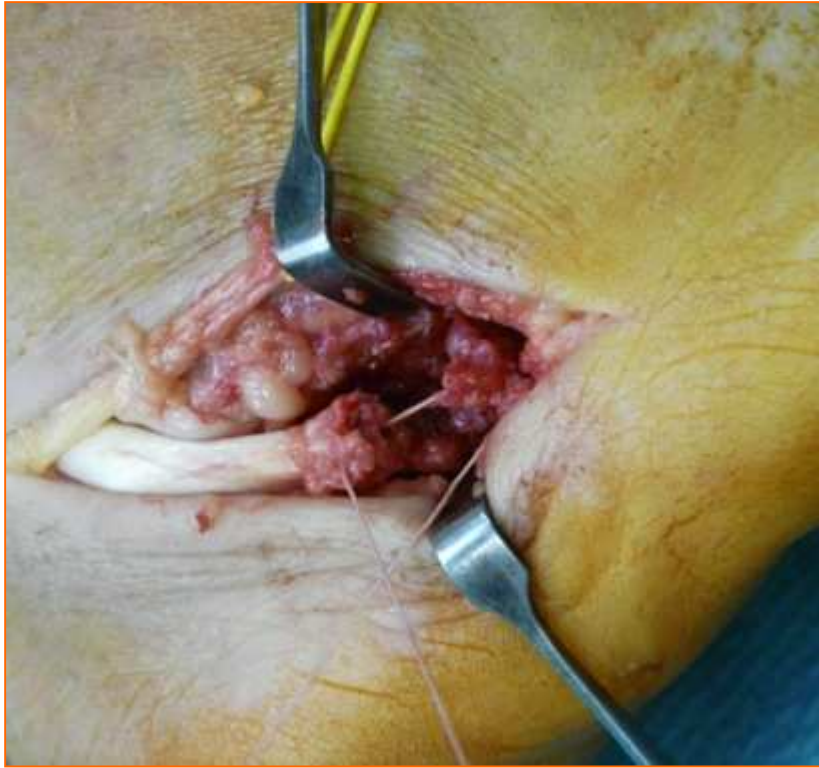



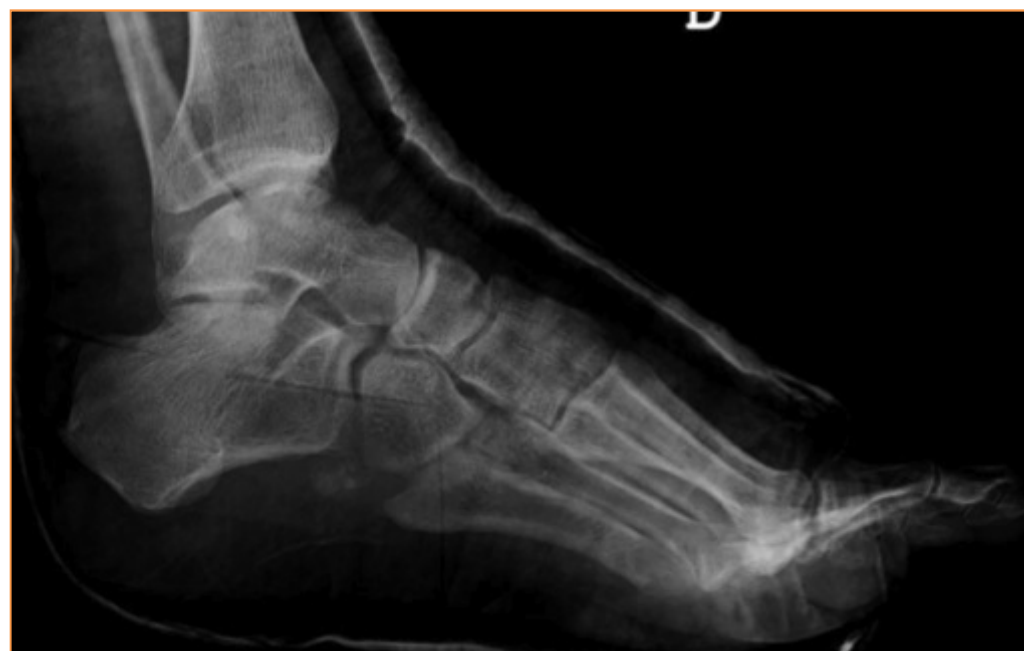
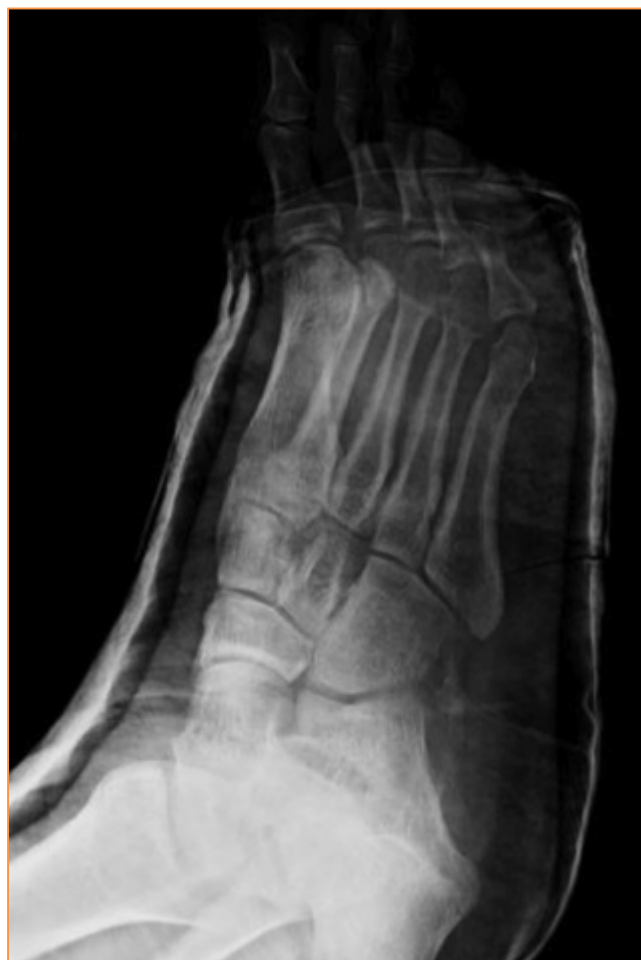











Bibliografía

Vincent James Sammarco MD, Daniel J. Cuttica DO, G. James Sammarco MD

Lasso Stitch with Peroneal Retinaculoplasty for Repair of Fractured Os Peroneum. A Report of Two Cases Clin Orthop Relat Res (2010) 468:1012–1017

J.M.LEMINOR Comparative anatomy and significance of the sesamoid bone of the peroneus longus muscle (os peroneum). J. Anat (1987), 151, 85-99.

Brion Benninger, Jessica Kloenne. The Clinical Importance of the Os Peroneum: A Dissection of 156 Limbs Comparing the Incidence Rates in Cadavers versus Chronological Roentgenograms The Foot and Ankle Online Journal 4 (2): 2



*Muchas gracias
Muito obrigado*

